

“Adjustable” Artificial Chordal Replacement for Repair of Mitral Valve Prolapse

J. Scott Rankin, MD, Ricardo E. Orozco, Tracey L. Rodgers, David D. Alfery, MD, and Donald D. Glower, MD

Centennial Hospital, Vanderbilt University, Nashville, Tennessee, Duke University Medical Center, Durham, North Carolina

Achieving a stable repair of mitral valve prolapse can be difficult in complex pathologies, and a 5% to 20% late reoperation rate exists with leaflet resection and reconstruction. During an 8-year period, prolapse was managed uniformly with “adjustable” Gortex (W. L. Gore & Associates Inc, Flagstaff, AZ) artificial chordal replacement and Carpentier ring annuloplasty (Edwards Lifesciences LLC, Irvine, CA), without leaflet resection. Artificial chords were placed initially in the papillary muscles, and then after ring annuloplasty they were adjusted to optimize length to the prolapsing segment(s).

Of 52 patients with prolapse, 100% were repaired successfully with artificial chords. Operative mortality was 1.9%, and 4, 6, and 8-year survivals were 87%, 81%, and 71%, respectively. Only 1 of 52 patients (1.9%) experienced late failure, and this patient was re-repaired with artificial chords. Thus, “adjustable” artificial chordal replacement facilitates uniform repair of mitral valve prolapse with a low late failure rate.

(Ann Thorac Surg 2006;81:1526–8)

© 2006 by The Society of Thoracic Surgeons

Mitral valve prolapse is a disease of chordal support, producing mitral regurgitation because of elongation or rupture of myxomatous chords. More than 2 decades ago, Carpentier (Edwards Lifesciences LLC, Irvine, CA) combined ring annuloplasty with leaflet resection and reconstruction to formalize mitral repair [1]. However, problems remain in the ability to repair more complex pathologies, and also left ventricular outflow tract obstruction can occur with leaflet resection [2]. Finally, late failure requiring reoperation occurs in 5% to 20% of patients [3, 4]. To address these issues, routine Gortex (W. L. Gore & Associates Inc, Flagstaff, AZ) [5] artificial chordal replacement was initiated in 1995 to repair all types of prolapse, abandoning leaflet resection altogether [6, 7]. This article presents the techniques used, as well as early and late efficacy data to support the method.

Technique

Over an 8-year period from November 1995 through November 2003 (median follow-up = 4 years), 52 patients underwent isolated mitral repair with or without coronary bypass for prolapse, constituting 100% of prolapse encountered during that period. Concurrently, 61 patients had isolated mitral valve replacement with or without coronary bypass (rheumatic = 44, prosthetic dysfunction = 6, endocarditis = 5, hypertrophic subaortic

stenosis = 4, calcification = 1, and papillary muscle rupture = 1). Repair also was performed in 48 additional patients (pure annular dilatation = 18, ischemic mitral regurgitation = 27, viral cardiomyopathy = 2, and rheumatic disease = 1).

Median sternotomy, cardiopulmonary bypass, and cold potassium cardioplegia were used in all patients. Coronary bypass was performed in 27%. Single chords were placed in 77%, and multiple chords in 23%. Chords were posterior only in 69%, anterior only in 20%, and chords were placed to both leaflets in 11%. Artificial chords to the left aspect of either leaflet were anchored to the anterior papillary muscle, and those to the right aspect of either leaflet, to the posterior papillary muscle. Each valve was evaluated both by pre-bypass transesophageal echocardiography and by forcefully injecting cold saline across the valve using a bulb syringe.

After confirmation of the prolapsing segment(s) (Fig 1A), pledgetted horizontal mattress sutures of 4-0 Prolene were placed longitudinally into each papillary muscle, passing one arm through the fibrous tip. Each anchor suture was tied firmly, and a double-armed Gortex vascular suture (2-0 or CV-3 is recommended) was then passed through the anchor suture but not tied (Fig 1B). The Gortex chord was placed into the ventricle in an organized way, and a “classic” Carpentier annuloplasty ring was sutured to the mitral annulus with interrupted mattress sutures of 2-0 Polydek supported with supra-annular Teflon felt pledgets.

With the ring in position, the Gortex chords were retrieved from the ventricle, and both needles were woven into the prolapsing segment, straddling the point of maximal prolapse (Fig 1C). Two or three bites were taken through the coaptation surface to the line of coap-

Accepted for publication Jan 10, 2005.

For four instructional videos on adjustable chordal replacement illustrating repair in 11 different anatomies, please see: www.jscottrankinmd.com.

Address correspondence to Dr Rankin, 2400 Patterson St, Ste 103, Nashville, TN 37203; e-mail: jsrankinmd@cs.com.

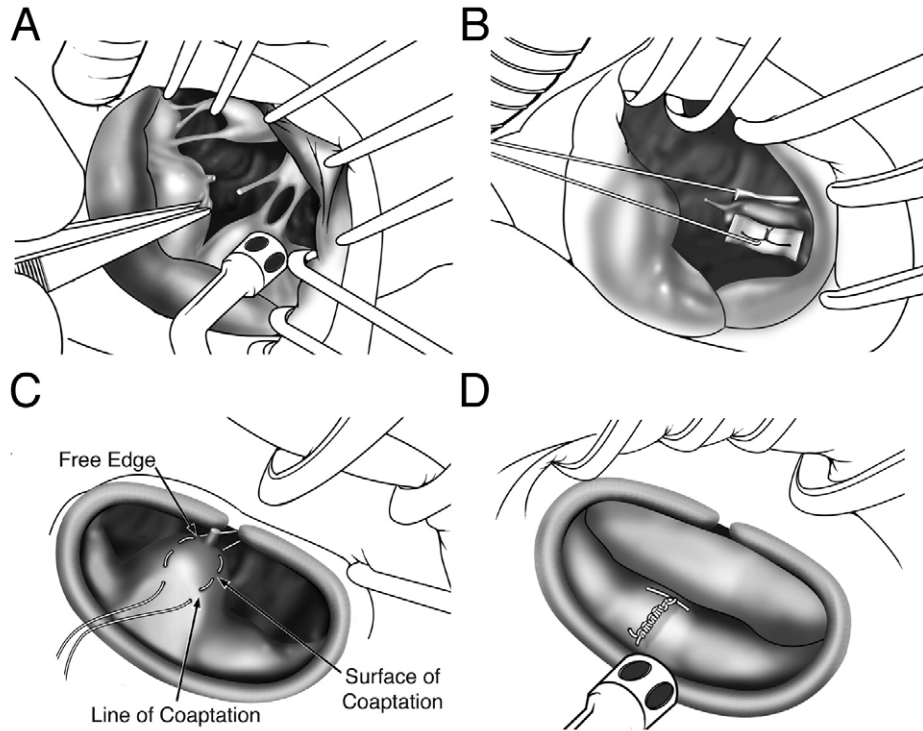


Fig 1. Sequential steps in "adjustable" artificial chordal replacement. (A) Confirmation of the prolapsing segment(s). (B) A double-armed Gortex (W. L. Gore & Associates Inc, Flagstaff, AZ) vascular suture (2-0 or CV-3 is recommended) is passed through the anchor suture but not tied. (C) With the ring in position, the Gortex chords are retrieved from the ventricle, and both needles are woven into the prolapsing segment, straddling the point of maximal prolapse. (D) After eight more knots are tied tightly against the clip, the suture is cut, and the clip is removed.

tation, with full thickness purchase to prevent disruption. The two arms of the suture were then tied on the atrial surface with a slip-knot, just tight enough to bring the leaflet to the annular plane, and a clip was placed lightly across the knot. Further chords were retrieved (if multiple chords were placed), passed through their designated segments, and similarly tied with slip knots. Pericardial pledgets were used if the leaflet tissue seemed fragile. Again the valve was tested by injecting cold saline across the leaflets. Often the first chordal length was too short or too long, and the leaflets would not seat properly in the annulus. The clip was then removed, the slip knot was lengthened or tightened 1 cm, and another clip was placed. The process was repeated until the valve was competent. Eight more knots were then tied tightly against the clip, the suture was cut, and the clip was removed (Fig 1D). Without tying carefully and tightly against the clip, it was difficult to make the final knot tight, creating a possibility for the knot to untie later. At the final testing, chordal length was adjusted just short enough to make the valve competent. After normal filling and outward displacement of the papillary muscles, the chords always tended to appear shorter by transesophageal echocardiography, and this phenomenon was considered as chordal lengths were determined. In the most difficult generalized prolapse, such as with a Barlow's valve, two Gortex sutures were positioned in the anterior, and two in the posterior papillary muscles. The anterior papillary muscle chords were placed to the left aspect of both leaflets, and the posterior papillary muscle chords to the right aspect of both leaflets. Prolapsing commissural cusps or smaller intervening segments were sutured to a segment supported by an artificial chord.

This study was approved by the Institutional Review Boards of Centennial Hospital and Duke University. Data were abstracted from hospital chart review, and follow-up was obtained by telephone in October and November 2003 (100% complete). Cumulative survival rates were generated using the Kaplan-Meier method.

Of the 52 prolapse patients, all had moderate to severe mitral regurgitation preoperatively, median age was 62 years, 41% were female, 30% had preoperative comorbidity, 9% had severe left ventricular dysfunction, 27% had coronary disease, and 27% experienced acute presentation. By post-bypass echocardiography, 50 had no residual leak, and 2 exhibited mild regurgitation. Outflow tract obstruction was not observed. Thirty-day mortality was 1.9%, and complications occurred in 17%. Median time to discharge was 7 days. No sternal infections or prosthetic endocarditis occurred. To a maximal follow-up of 8 years, 1 patient underwent reoperation (1.9%) for failure of repair, 3 years after artificial chords to the anterior leaflet. At surgery, rupture of a 4-0 Gortex suture was encountered, and the valve was re-repaired using 2-0 Gortex. On surface echocardiography, obtained in all surviving patients within 1 year of follow-up, only 2 additional patients (3.8%) had moderate echocardiographic leak, and are being managed medically with minimal symptoms. Kaplan-Meier survival at 4, 6, and 8 years was 87% (39 patients at risk), 81% (19 patients at risk), and 71% (9 patients at risk).

Comment

Artificial chordal replacement has several advantages for repair of mitral prolapse. First, chordal support is aug-

mented by Gortex sutures, and is not based solely on residual myxomatous chords. Second, chordal replacement does not require leaflet resection, and by preserving leaflet surface area, residual leak is minimized. Third, any prolapsing segment can be repaired, making it convenient to repair more complex pathologies. Fourth, chordal replacement can be adaptable to minimally invasive approaches [8]. Fifth, chordal replacement is associated with a low incidence of late valve failure. Sixth, outflow tract obstruction is avoided. The difficulty with chordal replacement has been obtaining optimal length, but the "adjustability" method seems to have solved this problem. Finally, failure of repair can occur because of chordal disruption from a papillary muscle or leaflet, chordal untying or rupture, or ring dehiscence. These causes can be minimized by papillary anchor sutures, full-thickness bites in the leaflets (with or without pledgets), tight knot tying, using 2-0 Gortex suture, and pledgetting annuloplasty ring sutures. At this point, "adjustable" artificial chordal replacement may be considered as a primary procedure for management of mitral valve prolapse.

References

1. Carpentier A. Cardiac valve surgery—the "French correction". *J Thorac Cardiovasc Surg* 1983;86:323.
2. Jebara VA, Mihaileanue S, Acar C, et al. Left ventricular outflow tract obstruction after mitral valve repair: results of the sliding leaflet technique. *Circulation* 1993;88:II3-10.
3. Mohty D, Orszulak TA, Schaff HV, et al. Very long-term survival and durability of mitral valve repair for mitral valve prolapse. *Circulation* 2001;104:1-7.
4. Braunberger E, Deloche A, Berrebi A, et al. Very long-term results (more than 20 years) of valve repair with Carpentier's techniques in nonrheumatic mitral valve insufficiency. *Circulation* 2001;104:18-11.
5. Vetter HO, Burack JH, Factor SM, et al. Replacement of chordae tendineae of the mitral valve using the new expanded PTFE suture in sheep. In: Bodnar E, Yacoub M, eds. *Biologic bioprosthetic valves*. New York: Yorke Medical Books, 1986:772-84.
6. Rankin JS, Orozco RE, Rodgers TL, et al. Early and late efficacy of routine chordal replacement for repair of mitral valve prolapse. *Circulation* 2003;108:IV 477.
7. Rankin JS, Orozco RE, Rodgers TL, et al. Several new considerations in mitral valve repair. *J Heart Valve Dis* 2004;13:399-409.
8. Nigro JJ, Schwartz DS, Bart RD, et al. Neochordal repair of the posterior mitral leaflet. *J Thorac Cardiovasc Surg* 2004;127:440-7.