

A New Mitral Valve Repair Strategy for Hypertrophic Obstructive Cardiomyopathy

J. Scott Rankin, Robert S. Binford, Thomas S. Johnston, John T. Matthews, David D. Alfery, A. Thomas McRae, Louis A. Brunsting III

Centennial Medical Center, Vanderbilt University, Nashville, TN, USA

Background and aim of the study: Previously, surgery for hypertrophic obstructive cardiomyopathy (HOCM) has consisted primarily of septal myectomy and/or resection of the anterior mitral leaflet with low-profile valve replacement. However, recent studies have shown that the anterior papillary muscle and chordal fan can contribute to obstruction, and also that significant mitral regurgitation (MR) may be encountered. Hence, a surgical procedure was devised to address all components of this disorder.

Methods: A 37-year-old man had a history of heart murmur and NYHA class IV symptoms, despite beta-blocker therapy. Echocardiography showed severe septal hypertrophy, systolic anterior motion (SAM) of the mitral valve, severe MR and a 185 mmHg resting outflow tract gradient. At surgery, the anterior papillary muscle was found to be medially displaced and contributing to outflow obstruction. The anterior papillary muscle and chordae were resected, a 'traditional' septal myectomy was performed, and a full annuloplasty ring placed. The mitral valve was

repaired by connecting the left aspect of the leaflets to the posterior papillary muscles, using Gore-Tex artificial chords.

Results: The patient recovered uneventfully. Interval echocardiography at one year showed a negligible outflow gradient, relief of SAM and mild residual MR. The patient currently is active, essentially asymptomatic, and not receiving any medical therapy.

Conclusion: Previous approaches to HOCM have been limited by a small incidence of recurrent outflow gradients, pacemaker requirement, persistent MR or complications of the prosthetic valves. By comprehensively addressing all components of outflow obstruction and mitral dysfunction, this combined procedure may produce better results in certain subsets of HOCM, with the excellent late prognosis of artificial chordal replacement.

The Journal of Heart Valve Disease 2008;17:642-647

Because the left ventricular outflow tract is bounded anatomically by the ventricular septum and the anterior mitral leaflet, the dynamic obstruction of hypertrophic obstructive cardiomyopathy (HOCM) can be relieved by resecting either component. During recent years, most surgeons have practiced a traditional transaortic septal myectomy, as popularized by Morrow and associates (1,2). However, Cooley and colleagues have advocated a routine resection of the anterior mitral leaflet with low-profile valve replacement, especially in patients with significant mitral regurgitation (MR) (3,4). Recent experience suggests that, while both of these approaches perform well, each has a sig-

nificant incidence of residual problems. Mitral replacement is associated with early and late prosthetic valve-related complications, and the more recently described 'extended myectomy', although effective in acutely reducing gradients, can be fraught with persistent systolic anterior motion (SAM), recurrent gradients, residual MR and a modest pacemaker requirement (5,6). Herein is reported a more comprehensive procedure that addresses all of these issues, and could improve late results, especially in patients with pronounced mitral abnormalities.

Clinical material and methods

The patient

A 37-year-old man had a history of heart murmur and NYHA class IV angina and heart failure, despite beta-blocker therapy. Transesophageal echocardiography (TEE) revealed the presence of marked septal

Address for correspondence:
J. Scott Rankin MD, 320 Lynnwood Blvd., Nashville, TN 37205, USA
e-mail: jsrankinmd@cs.com

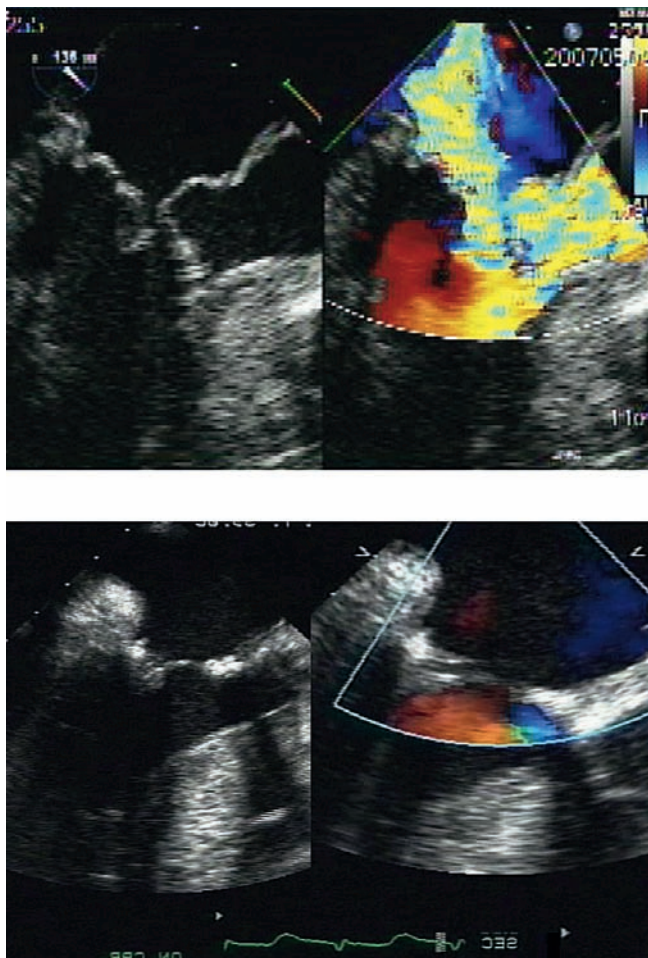


Figure 1: Top panels: Preoperative transesophageal echocardiogram showing SAM, anterior papillary muscle prolapse into the left ventricular outflow tract (LVOT), severe mitral regurgitation and a 185 mmHg outflow tract gradient. Bottom panels: Intraoperative transesophageal echocardiogram after repair showing a fully open LVOT, no SAM, no residual MR and a negligible outflow gradient.

hypertrophy, severe MR and a resting outflow tract gradient (peak/mean) of 185/87 mmHg. Systolic anterior motion of the mitral valve was pronounced, and there was also evidence of prolapse of the anterior papillary muscle into the outflow tract (Fig. 1). The left ventricular ejection fraction (LVEF) was 0.70, and coronary angiography negative.

Note: This report has been submitted with the signed informed consent of the patient to present details of surgical data, images and follow up. An IRB-exempt opinion was also obtained from Western IRB for Centennial Medical Center, Nashville, TN, USA.

Surgical procedure

On 10th May 2007, the patient underwent surgery via a median sternotomy, standard cardiopulmonary

bypass, bicaval cannulation, antegrade St. Thomas' Hospital cold potassium cardioplegia, and the Daily heart jacket for topical hypothermia. At surgery, the anterior papillary muscle arose from a medial-superior origin (Fig. 2), and seemed to prolapse into the outflow tract, contributing to obstruction. A schematic illustration is shown in Figure 3. The chordae were foreshortened, and the left aspect of the anterior leaflet arose almost directly from the papillary muscle tip. Through an oblique aortotomy, a traditional septal myectomy was performed by resecting the fibrous endocardial thickening and underlying muscle of the hypertrophied septum from the area left of the conduction system to the mitral valve annulus. A traditional Morrow trough was created in the left aspect of the septal bar (Fig. 3). Through a left atriotomy, all of the chordal attachments from the left aspects of both leaflets to the anterior papillary muscle were divided, and a fibrotic anterior papillary muscle and foreshortened chordal fan were resected (Figs. 2 and 3). The left aspects of both leaflets were reattached to posterior papillary heads using four 2-0 Gore-Tex artificial chords, pulling the anterior leaflet in a posterior direction, and out of the outflow tract. Two chords were placed to the commissural aspect of both leaflets, and two to the central aspect. After inserting a full annuloplasty ring, the chordal lengths were adjusted (7,8) to achieve leaflet symmetry and competence (Figs. 2 and 3), and the procedure was concluded.

Results

Post-bypass TEE showed complete mitral competence, no evidence of SAM, and an open outflow tract with a 10/5 mmHg (peak/mean) gradient (Fig. 1). The hemodynamics and conduction otherwise were normal, and the patient recovered uneventfully. Interval transthoracic echocardiography at one week after surgery showed essentially the same findings, and the patient was discharged on no cardiac medications, except aspirin. He subsequently became asymptomatic from an anginal viewpoint, but continued to have mild exertional dyspnea. Repeat TEE at one year postoperatively showed mild MR, no SAM, and a (peak/mean) outflow tract gradient of 16/9 mmHg on no cardiac medications. The LVEF was 0.70, but the left ventricular hypertrophy had not regressed appreciably.

Discussion

Surgical therapy for HOCM has evolved significantly over the past 50 years. Brock first identified the obstruction as subvalvar and dynamic (9), while Kirklin and Ellis performed a successful transventricular septal myectomy in 1959 (10). In 1960, Morrow cre-

ated a transaortic septal myotomy and later converted to transaortic myectomy (1,2,11). From the very first series, however, septal myectomy - while generally effective - was associated with a small but significant incidence of complications, such as incomplete relief of gradients, persistent mitral valve dysfunction, conduction defects and ventricular septal perforation. Teare first defined mitral valve abnormalities in HOCM (12), while Bjork et al. suggested that they might contribute to the pathophysiology (13). Dinsmore et al. noted the frequency of mitral dysfunction and the 50-70% incidence of significant MR (14). Fix and colleagues, in 1964, further hypothesized that anterior leaflet and/or papillary muscle anomalies could be a 'primary factor' in the obstructive pathophysiology (15), and proposed that it "...would be worthwhile to consider the possibility of a plastic operation on the anterior mitral leaflet [or a] mitral valve prosthesis". This concept was the basis of Cooley's approach of leaflet resection and low-profile mitral valve replacement (3,4), which has been quite successful in relieving gradients (16-18). However, a significant incidence of early and late valve-related complications exists after prosthetic valve replacement, which clearly limits this procedure.

Based on the findings of recent series advocating septal myectomy, it is clear that residual problems also exist with this operation, with less than optimal results occurring in up to perhaps 20% of patients at a mean follow up of four years (19). Moreover, it is likely that complications and recurrences increase with a longer period of follow up (17,20,21). In straightforward cases managed with extended septal myectomy and experiencing gradient reduction (19), 52% of patients manifested persistent SAM, some developed worsening MR requiring interval mitral replacement, and 10-20% required pacemakers over time. A few ventricular septal defects also occurred, but these were managed with surgical closure. In the 15-20% of patients with more severe mitral anomalies who required mitral procedures in addition to myectomy, the outcomes have been less predictable (6,22). Specifically, operative mortality has been 5-15% when mitral procedures were required, only half of the valves could be repaired using standard techniques, competence deteriorated significantly over time after repair, and many repairs required interval conversion to replacement. Thus, while septal myectomy produces 'satisfactory' results in most patients (20,22-24), a potential for improvement does exist, especially in those with serious mitral dysfunction (6).

Mitral insufficiency is common in HOCM, and mitral structural abnormalities exist in a significant proportion of patients. A report from the Royal Brompton Hospital in 1997 (25) described an 'abnormal papillary muscle of the mitral valve obstructing the outflow trac-



Figure 2: Top panel: The chordal attachments of the anterior papillary muscle to the left half of both leaflets have been divided, and the fibrotic and hypertrophied anterior papillary muscle, arising anomalously to the left and superiorly, is being excised flush with the ventricular endocardium. Center panel: The detached left halves of both leaflets are evident, and a posterior papillary muscle head is identified, to which the leaflets will be reattached with Gore-Tex artificial chords. Bottom panel: View of the fully competent valve after repair. The ventricle has been pressurized with cold saline, and there is no residual leak. The four artificial chords constructed from the posterior papillary muscle to the left halves of both leaflets are evident.

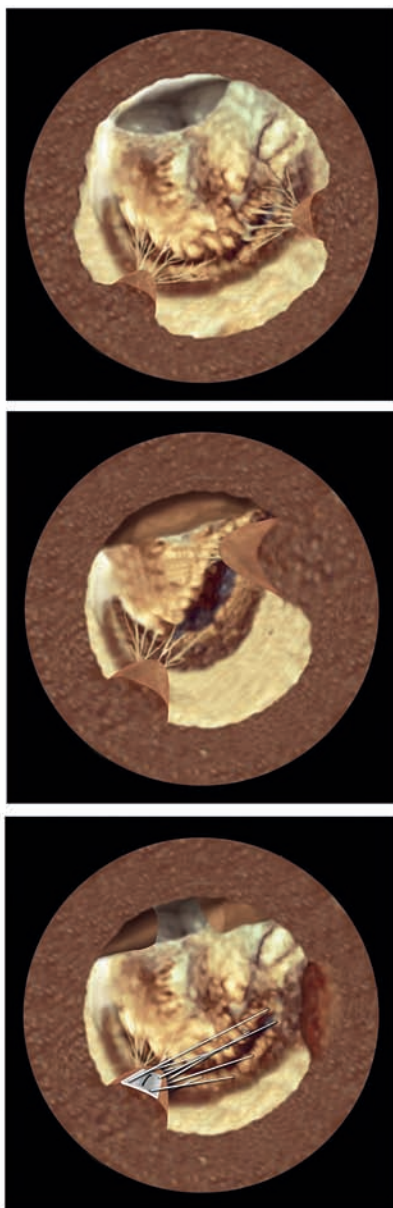


Figure 3: Top panel: Diagrammatic representation of normal mitral valve coaptation, and normal relationships of the mitral valve, aortic valve and outflow tract. Center panel: In HOCM, the ventricle and papillary muscles are hypertrophied, and an asymmetric bar of septal hypertrophy is present. The anterior papillary muscle originates anomalously toward the septum, and both the anterior leaflet and anterior papillary muscle exhibit systolic anterior motion, abutting the septal bar and creating outflow obstruction. Bottom panel: After repair, the traditional septal myectomy is evident. The anterior papillary muscle has been resected, and the left halves of both mitral leaflets have been reattached to the posterior papillary muscle, effectively pulling the leaflets posteriorly and relieving the outflow obstruction. The mitral valve also has recovered normal coaptation and leaflet position. The repair ring would be on the other (or atrial) side of the mitral valve and re-established normal annular geometry.

t' necessitating mitral replacement, and many reports (6,26) have documented 'anomalous papillary muscles', similar to the present case. Several echocardiographic studies have noted the prevalence of mitral abnormalities to be even higher than previously thought (6,27), and suggested that patients with significant mitral dysfunction should undergo more primary mitral procedures. In several recent reports, reparative techniques have been described to correct the mitral anomalies (6,28-34). These include: mitral repair with chordal transfer; mitral leaflet plication or resection; secondary chordal division; anterior leaflet augmentation or 'cephalad suspension'; and papillary muscle release or realignment. The current report further extends these efforts by simultaneously relieving all aspects of outflow obstruction and formally repairing the mitral valve. Based on the result obtained in the present patient, this more comprehensive approach appears to be worthy of future application.

From the viewpoint of relieving outflow obstruction and MR, the prognosis of the proposed operation should be good. The outflow tract is fully opened, the obstructing papillary muscle is resected, SAM is relieved by artificial chordal transposition, and the mitral valve is competent. Because the myectomy is of a traditional or conservative magnitude, conduction defects and pacemaker requirement should be minimal, and the long-term outcome might be limited primarily by the durability of the mitral repair. This type of artificial chordal repair has been routine at the present authors' center for patients with mitral prolapse over the past 13 years (7,8), and late failure/reoperation rates have been extremely low. Patients require only aspirin anticoagulation, and valve-related complications have been negligible (35,36), thereby justifying extension into more complex disorders such as HOCM or rheumatic disease (37,38). Thus, it might be projected that this procedure could have the advantages of both myectomy and mitral replacement, without many of the disadvantages. It is unclear what percentage of HOCM patients might be candidates for this more comprehensive approach, but it possibly could be quite useful, especially in those with more significant mitral dysfunction. Surgical myectomy has been shown to be superior to medical therapy or septal alcohol ablation (39,40), and the proposed procedure - or a variant thereof - could further improve surgical results.

It is conceivable that Fix's concept of obstructing mitral anomalies being a 'primary factor' in the development of HOCM (15) may be more important than previously thought. Support for the 'obstruction' rather than the 'primary myopathy' hypothesis is derived from the study conducted at the Mayo Clinic which showed a significant regression of hypertrophy

after relief of obstruction in a selected group of patients (41). The lack of hypertrophy regression at one year in the present patient, despite relief of outflow obstruction, does raise some concern however and suggests that persistent primary cardiomyopathy might be problematic in some patients. Alternatively, it is possible that this patient will continue to have 'mid-ventricular obstruction' from the remaining papillary muscles and an incomplete unloading of the apical left ventricle. In fact, the ventricular walls on the one-year echocardiogram were seen essentially to be touching during systole. Perhaps a more extensive resection of other hypertrophied papillary muscles (see Fig. 2) might be considered in future patients, as complete papillary resection combined with mitral repair would be feasible using artificial chordal replacement techniques. Finally, the etiology of outflow tract obstruction in HOCM is likely protean, with both hypotheses contributing. In either case, a more consistent correction of mitral abnormalities, when present, could be useful.

In conclusion, the outflow tract obstruction of HOCM can involve a combination of asymmetric septal hypertrophy and various abnormalities of the mitral valve. By addressing all components of obstruction, a more comprehensive surgical procedure, involving papillary muscle resection, artificial chordal transposition and mitral valve repair, in addition to septal myectomy, may have application in selected high-risk HOCM pathologies, with potentially fewer early and late complications. Further application of this type of procedure seems indicated.

Addendum

During the submission/review/revision phase of this report, two additional patients presented with this type of HOCM anatomy, severe MR and high resting gradients. When identical procedures to the present patient were performed, the relief of outflow obstruction, correction of MR and anatomic results were equivalent to those achieved for the present case.

References

1. Morrow AG, Lambrew CT, Braunwald E. Idiopathic hypertrophic subaortic stenosis. *Circulation* 1964;29-30(Suppl.IV):IV120-IV129
2. Morrow AG, Reitz BA, Epstein SE, et al. Operative treatment in hypertrophic subaortic stenosis. *Circulation* 1975;52:88-97
3. Cooley DA, Leachman RD, Wukasch DC. Diffuse muscular subaortic stenosis: Surgical treatment. *Am J Cardiol* 1973;31:1-6
4. Cooley DA, Wukasch DC, Leachman RD. Mitral valve replacement for idiopathic hypertrophic

- subaortic stenosis. *J Cardiovasc Surg* 1976;17:380-387
5. Smedira NG, Lytle BW, Lever HM, et al. Current effectiveness and risks of isolated septal myectomy for hypertrophic obstructive cardiomyopathy. *Ann Thorac Surg* 2008;85:127-134
6. Kaple RK, Murphy RT, DiPaola LM, et al. Mitral valve abnormalities in hypertrophic obstructive cardiomyopathy: Echocardiographic features and surgical outcomes. *Ann Thorac Surg* 2008;85:1527-1535
7. Rankin JS, Orozco RE, Addai TR, et al. Several new considerations in mitral valve repair. *J Heart Valve Dis* 2004;13:399-409
8. Rankin JS, Orozco RE, Rodgers TL, et al. 'Adjustable' artificial chordal replacement for repair of mitral valve prolapse. *Ann Thorac Surg* 2006;81:1526-1528
9. Brock R. Functional obstruction of the left ventricle. *Guy's Hosp Rep* 1959;108:126-143
10. Kirklin JW, Ellis FH. Surgical relief of diffuse subvalvular aortic stenosis. *Circulation* 1961;24:739-742
11. Morrow AG, Braunwald E. Functional aortic stenosis. *Circulation* 1959;20:181-189
12. Teare D. Asymmetrical hypertrophy of the heart in young adults. *Br Heart J* 1958;20:1-8
13. Bjork VO, Hultquist G, Luden H. Subaortic stenosis produced by an anteriorly placed anterior mitral leaflet. *J Thorac Cardiovasc Surg* 1959;41:659-666
14. Dinsmore RF, Sanders CA, Harthorne JW. Mitral regurgitation in idiopathic hypertrophic subaortic stenosis. *N Engl J Med* 1966;275:1225-1228
15. Fix P, Moberg A, Soderberg A, et al. Muscular subvalvular aortic stenosis. Abnormal anterior mitral leaflet possibly the primary factor. *Acta Radiol* 1964;2:177-184
16. McIntosh CL, Greenberg GJ, Maron BJ, et al. Clinical and hemodynamic results after mitral valve replacement in patients with obstructive hypertrophic cardiomyopathy. *Ann Thorac Surg* 1989;47:236-246
17. Roberts CS, McIntosh CL, Brown PS, Jr., et al. Reoperation for persistent outflow obstruction in hypertrophic cardiomyopathy. *Ann Thorac Surg* 1991;51:455-460
18. Walker WS, Reid KG, Cameron EW, et al. Comparison of ventricular septal surgery and mitral valve replacement for hypertrophic obstructive cardiomyopathy. *Ann Thorac Surg* 1989;48:528-534
19. Smedira NG, Lytle BW, Lever HM, et al. Current effectiveness and risks of isolated septal myectomy for hypertrophic obstructive cardiomyopathy. *Ann Thorac Surg* 2008;85:127-134
20. Schonbeck MH, Brunner-LaRocca HR, Vogt PR, et

- al. Long-term follow up in hypertensive obstructive cardiomyopathy after myectomy. *Ann Thorac Surg* 1998;65:1207-1214
21. Minakata K, Dearani JA, Schaff HV, et al. Mechanisms for recurrent left ventricular outflow tract obstruction after septal myectomy for obstructive hypertrophic cardiomyopathy. *Ann Thorac Surg* 2005;80:851-856
 22. Schulte HD, Bircks WH, Loesse B, et al. Prognosis of patients with hypertrophic obstructive cardiomyopathy after transaortic myectomy. Late results up to twenty-five years. *J Thorac Cardiovasc Surg* 1993;106:709-717
 23. Merrill WH, Friesinger GC, Graham TP, Jr., et al. Long-lasting improvement after septal myectomy for hypertrophic obstructive cardiomyopathy. *Ann Thorac Surg* 2000;69:1732-1736
 24. Robbins RC, Stinson EB. Long-term results of left ventricular myotomy and myectomy for obstructive hypertrophic cardiomyopathy. *J Thorac Cardiovasc Surg* 1996;111:586-594
 25. Kon MWS, Grech ED, Ho SY, et al. Anomalous papillary muscle as a cause of left ventricular outflow tract obstruction in an adult. *Ann Thorac Surg* 1997;63:232-234
 26. Minakata K, Dearani JA, Nishimura RA, et al. Extended septal myectomy for hypertrophic obstructive cardiomyopathy with anomalous mitral papillary muscles or chordae. *J Thorac Cardiovasc Surg* 2004;127:481-489
 27. Song JM, Fukuda S, Lever HM, et al. Asymmetry of systolic anterior motion of the mitral valve in patients with hypertrophic obstructive cardiomyopathy: A real-time three-dimensional echocardiographic study. *J Am Soc Echocardiogr* 2006;19:1129-1135
 28. Balam SK, Sherrid MV, Derosé JJ, Jr., et al. Beyond extended myectomy for hypertrophic cardiomyopathy: The resection, plication, release (RPR) repair. *Ann Thorac Surg* 2005;80:217-223
 29. van Son JAM, Anderson RH, Mohr FW. Cephalad resuspension of aortic leaflet of the mitral valve in hypertrophic obstructive cardiomyopathy. *Ann Thorac Surg* 1998;66:242-244
 30. Opfermann UT, Doll N, Walther T, et al. Combined mitral valve repair, LVOT myectomy, and left atrial cryoablation therapy. *Interact CardioVasc Thorac Surg* 2003;2:501-502
 31. van der Lee C, Kofflard MJM, van Herwerden LA, et al. Sustained improvement after anterior mitral leaflet extension and myectomy in hypertrophic obstructive cardiomyopathy. *Circulation* 2003;108:2088-2094
 32. Bryant R, III, Smedira NG. Papillary muscle realignment for symptomatic left ventricular outflow tract obstruction. *J Thorac Cardiovasc Surg* 2008;135:223-224
 33. Matsuda H, Nomura F, Kadoba K. Transatrial and transmitral approach for left ventricular myectomy and mitral valve plication for diffuse-type hypertrophic obstructive cardiomyopathy: A novel approach. *J Thorac Cardiovasc Surg* 1996;112:195-196
 34. Aharonyan A, Zohrabyan HG, Manukyan V, et al. Complete excision of secondary chordae of the anterior mitral leaflet as an adjunct in surgical management of hypertrophic obstructive cardiomyopathy in pediatric patients. *J Thorac Cardiovasc Surg* 2001;122:815-816
 35. Chiappini B, Sanchez A, Noirhomme P, et al. Replacement of chordae tendineae with polytetrafluoroethylene (PTFE) sutures in mitral valve repair: Early and long-term results. *J Heart Valve Dis* 2006;15:657-663
 36. Salvador L, Mirone S, Bianchini R, et al. Twenty-year experience of mitral valve repair with artificial chordae in 608 patients. *J Thorac Cardiovasc Surg* 2008;135:1280-1287
 37. Rankin JS, Sharma MK, Michel JR, et al. A new method of mitral valve repair for rheumatic disease. *J Heart Valve Dis* 2008;17:614-619
 38. Rankin JS, Alfery DD, Orozco RA, et al. Techniques of artificial chordal replacement for mitral valve repair: Use in multiple pathologic disorders. *Op Tech Thorac Cardiovasc Surg* 2008;13:74-82
 39. Ralph-Edwards A, Woo A, McCrindle BW, et al. Hypertrophic obstructive cardiomyopathy: Comparison of outcomes after myectomy or alcohol ablation adjusted by propensity score. *J Thorac Cardiovasc Surg* 2005;129:351-358
 40. Ommen SR, Maron BJ, Olivetto I, et al. Long-term effects of surgical septal myectomy on survival in patients with obstructive hypertrophic cardiomyopathy. *J Am Coll Cardiol* 2005;46:470-476
 41. Deb SJ, Schaff HV, Dearani JA, et al. Septal myectomy results in regression of left ventricular hypertrophy in patients with hypertrophic obstructive cardiomyopathy. *Ann Thorac Surg* 2004;78:2118-2122